

# Nonobvious Obstructive Meibomian Gland Dysfunction

Caroline A. Blackie, OD, PhD,\*† Donald R. Korb, OD,\*† Eric Knop, MD, PhD,‡ Raman Bedi, MD,†§ Nadja Knop, MD, PhD,‡ and Edward J. Holland, MD¶

**Abstract:** This review presents the rationale and supporting data for a recent paradigm shift in our understanding of meibomian gland dysfunction (MGD). The historical understanding of MGD has been that of an infectious hypersecretory disorder with obvious signs of inflammation, hypersecretion, and purulent excreta. The current understanding of MGD now includes the polar concept of a less obvious or nonobvious type of hyposecretory obstructive MGD, where inflammation and other signs of pathology may be absent unless special examination techniques are employed. A new term, nonobvious obstructive MGD (NOMGD), is used to describe what may be the most common form of obstructive MGD. Obstructive MGD is an area of growing importance because obstructive MGD is now recognized to be the most common cause of evaporative dry eye, and because NOMGD seems to be the precursor to obvious obstructive MGD, it is also an important area to understand. The prevalence of NOMGD seems to be very high but currently significantly underdiagnosed. This review presents the relevant anatomy and physiology, concepts of obstructive MGD, the usual absence of inflammation in obstructive MGD, nomenclature and classification of obstructive and NOMGD, clinical diagnosis of NOMGD emphasizing the necessity for diagnostic expression, the use of a new instrument for diagnostic expression providing a standardized method of assessing meibomian gland functionality, the complementary roles of the aqueous and lipid layers, and the specific treatment of NOMGD, emphasizing that the success of treatment of all forms of obstructive MGD is dependent on the relief of the obstruction.

**Key Words:** nonobvious obstructive meibomian gland dysfunction, MGD, evaporative dry eye, meibomian gland functionality

(*Cornea* 2010;29:1333–1345)

Received for publication July 21, 2009; revision received January 11, 2010; accepted January 17, 2010.

From the \*Korb Associates, Boston, MA; †TearScience Inc. Morrisville, NC; ‡Research Laboratory of the Department of Ophthalmology CVK, Charité, Universitätsmedizin Berlin, Berlin, Germany; §Iris Advanced Eye Centre, CMC Hospital, Chandigarh, India; and ¶Cincinnati Eye Institute, Edgewood, KY.

Sources of Support: Korb Associates, Boston, MA and TearScience, Morrisville, NC.

C. A. Blackie is an employee of TearScience, Inc. D.R. Korb is a consultant for both Korb Associates and TearScience Inc., R. Bedi is a consultant for TearScience, Inc, and E. Knop, N. Knop, and E. J. Holland are not employees of either organization.

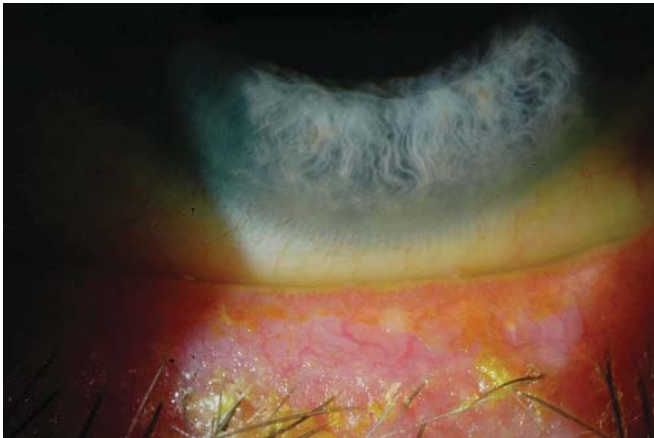Reprints: Caroline A. Blackie, Korb Associates, 400 Commonwealth Avenue, Unit #2, Boston, MA 02215 (e-mail: cblackie@tearscience.com).

Copyright © 2010 by Lippincott Williams & Wilkins

The purpose of this review is to present a recent paradigm shift in our understanding of meibomian gland dysfunction (MGD). Historically, MGD, considered an infectious disorder with obvious signs of inflammation, hypersecretion, and purulent excreta, has become an area of acute interest, as is evidenced by increasing literature and major reviews.<sup>1–6</sup> MGD is a complex disease, and the term MGD has become a rubric for many different meibomian gland abnormalities altering gland function, among which may be complete or partial obstruction of individual glands. This review will focus on a form of MGD where inflammation and other signs of pathology may be minimal and thus nonobvious or absent altogether, requiring diagnostic expression for diagnosis. We have chosen a new term, nonobvious obstructive MGD (NOMGD), to provide a succinct and recognizable descriptor for this condition. We further believe, on the basis of our experience, that it is important to clearly distinguish and communicate the nature of this condition because NOMGD is both the most common form of obstructive MGD and cause of evaporative dry eye (EDE). By definition, “nonobvious” means not easily seen, discovered, or understood. Because the condition we are describing is by definition nonobvious and because nonobvious has been used to convey this concept in science and medicine previously,<sup>7–11</sup> “nonobvious” is the most appropriate term for the type of MGD, NOMGD, reviewed in this article.

Obstructive MGD is an area of growing importance because obstructive MGD is now recognized to be the most common cause of EDE<sup>4–6,12–14</sup> and because NOMGD is likely the precursor to obvious obstructive MGD. Supporting the concept of a paradigm shift in our understanding of MGD and the critical role of the meibomian glands in dry eye, the prestigious Tear Film and Ocular Surface Society stated that “It is important to note that MGD may be the leading cause of dry eye syndrome.”<sup>15</sup> The Tear Film and Ocular Surface Society then initiated an international workshop with a mission of creating an evidence-based report on MGD, scheduled for publication in 2010.

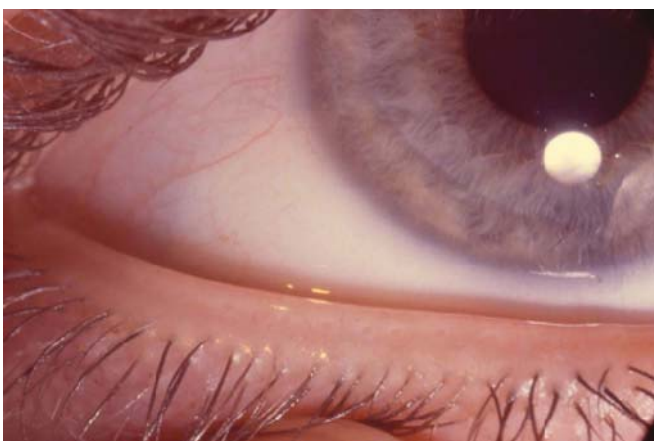The historical concept of MGD as a hypersecretory disorder with obvious signs of infection and inflammation (Fig. 1) is in polar contrast to NOMGD (Fig. 2), a hyposecretory disorder resulting in inadequate lipid for the formation of the lipid layer. Furthermore, because stagnation of meibomian gland secretion could result in subclinical intraductal inflammation (and/or infection), not readily observable with standard clinical techniques, early obstructive MGD could be nonobvious but not necessarily without preclinical inflammation or infection. The growing importance of obstructive MGD prompted this first review on what is most likely its usual form, NOMGD.



**FIGURE 1.** Obvious MGD. The eyelid is slightly everted with minimal digital pressure applied slightly below the eyelashes. The lower eyelid lashes evidence seborrheic scaling. The eyelid and eyelid margin evidence obvious inflammation and telangiectasia. The very minimal digital pressure resulted in purulent secretion.

### ANATOMY AND PHYSIOLOGY

The correct anatomical term for meibomian glands is tarsal glands; however, because of common usage, meibomian glands will be used in this review. Meibomian glands are modified sebaceous glands numbering 25–40 in the upper tarsus and 20–30 in the lower.<sup>1,16</sup> The glands are tubuloacinar holocrine glands vertically embedded in the tarsal plate and opening onto the eyelid margin just anterior to the mucocutaneous junction.<sup>17</sup> The epithelium of the ducts is lined by stratified squamous keratinized epithelium but with only partial keratinization as compared with the skin.<sup>18</sup> The secretion of the glands consist of various polar and nonpolar lipids, especially phospholipids, sterol esters, wax esters, and



**FIGURE 2.** NOMGD. The eyelid is slightly everted with minimal digital pressure applied slightly below the eyelashes. The eyelid, lashes, and eyelid margins are without inflammation or other pathological signs. The meibomian glands could be normal or obstructed; therefore, diagnostic expression is required to determine meibomian gland functionality.

cholesterol<sup>2,19–28</sup> with a broad range of 32–45°C reported for the melting point of the contents of the meibomian glands.<sup>3,13,29,30</sup> This broad range is probably the result of differing measurement methodologies and the composition of the secretion.

Regulation of the secretion is done neurally and hormonally.<sup>31</sup> The glands receive sensory, autonomic, and peptidergic innervations, the exact functions of which are not known.<sup>31,32</sup> The glands also have receptors for androgens and estrogens.<sup>32</sup> Androgens are reported to increase the activity of meibomian glands, similar to its effect on the sebaceous glands of the skin.<sup>31</sup> The estrogens have an opposite effect on the glands.<sup>31,32</sup>

The contents of the meibomian glands are released onto the eyelid margin and then form the lipid layer of the tear film. The lipids secreted by the meibomian glands consist of polar and nonpolar lipids.<sup>2,19–23,25</sup> Polar lipids, which mainly consist of phospholipids, interact with the lipophilic proteins in the tears such as lipocalin and help in the interaction between the hydrophilic aqueous tears and the hydrophobic layer of nonpolar lipids externally.<sup>33,34</sup>

The lipid layer, a function of the meibomian gland secretion, decreases the evaporative loss of tears,<sup>35</sup> maintains stability of aqueous film,<sup>36</sup> lowers the surface tension of tears drawing water into the tear film,<sup>37</sup> thickens the aqueous phase, and provides a smooth optical surface.<sup>5</sup> Other important functions ascribed to the lipid layer include prevention of tear overflow, prevention of maceration of the skin of the eyelid margin by tears, and prevention of tear film contamination by sebaceous gland secretions of the facial skin.<sup>38</sup>

### THE CONCEPTS OF OBSTRUCTIVE MGD

Before the 1970s, meibomian gland disorders were understood to be a manifestation of inflammation of the meibomian glands with hypersecretion, often associated with seborrheic blepharitis, and the etiopathogenesis was primarily attributed to bacterial infection (especially *Staphylococcus aureus*).<sup>39</sup> Contrary to the prevailing emphasis on hypersecretion, Keith<sup>40</sup> published an obstructive mechanism (keratinized epithelia in the gland orifices) for what he referred to as end stage severe seborrheic blepharitis, where no oil could be expressed from the glands. McCulley and Sciallis<sup>41</sup> were the first to report stagnation of the meibomian secretions with consequences of reduced tear breakup time (BUT) and superficial punctate keratopathy in a group of patients with blepharitis with minimal inflammatory signs anterior to the grey line.<sup>41</sup> The superficial punctate keratopathy had the characteristics seen in conditions with a known unstable tear film and not of those experimentally produced by *Staphylococcus* toxin.<sup>41</sup> Thus, findings by McCulley and Sciallis<sup>41</sup> on stagnation of meibomian gland secretion, with no clear sign of infection, introduced the concept of meibomian gland obstruction in the absence of disease.

The first evidence for meibomian gland obstruction in the absence of any obvious clinical signs was published by Korb and Henriquez.<sup>42</sup> Studying a group of patients who were referred for contact lens intolerance in the absence of any obvious clinical cause, they discovered that these patients had

significant meibomian gland obstruction. They presented histopathological data supporting a proposed mechanism of obstruction where desquamated epithelial cells aggregated into keratotic clusters obstructing the meibomian duct and suggested that the keratotic clusters were the result of increased epithelial turnover within the meibomian duct.<sup>42</sup>

In 1981, after the analysis of primate, rabbit, steer, and human specimens, Jester et al<sup>43</sup> hypothesized that the early stages of MGD were characterized by hyperkeratinization of the meibomian gland ductal epithelium. In 1982, Gutgesell et al<sup>44</sup> examined the meibomian glands of male patients with MGD, undergoing ectropion or entropion repair and brought additional histopathological evidence to the ductal hyperkeratinization theory. This was further supported by Nicoladies et al<sup>24</sup> in 1989 in their rabbit model of MGD. Combined, the histopathological data from both humans<sup>42</sup> and rabbits<sup>24</sup> with meibomian gland obstruction demonstrated hyperkeratinization and sloughing of keratinized cells into ducts, resulting in narrowing of ducts and obstruction of individual glands. Similar to Straatsma's<sup>45</sup> earlier description of cystic degeneration of human meibomian glands, Gutgesell et al<sup>44</sup> also noted that many of the acini in their male patients with MGD had undergone squamous metaplasia and were completely devoid of secretory contents. These changes were thought to represent pressure atrophy as a consequence of meibomian gland obstruction.<sup>44</sup>

In 1985, Robin et al<sup>46</sup> demonstrated that transillumination infrared biomicroscopy findings in humans correlate well to earlier histopathological observations, increasing the evidence in favor of the hyperkeratinization and obstruction theory. Finally, Ong et al<sup>47</sup> in 1991 documented the presence of a higher concentration of keratin in meibomian gland secretions in patients with MGD, providing further evidence supporting the hyperkeratinization hypothesis.

In 1985, Seal et al<sup>48</sup> demonstrated that their patients with meibomitis did not evidence infection. While obstruction of the glands and infection of the glands are not mutually exclusive before the research performed from 1977 to 1985, it was not clear that obstruction occurring in the absence of infection or cicatricial disease could lead to significant dry eye. As our awareness of the presence of meibomian gland obstruction in the absence of obvious infection and inflammation has grown so has the need for improved diagnosis and classification of the disease.

### Absence of Signs of Inflammation in Obstructive MGD

The first report that obstruction of human meibomian glands was not always accompanied by inflammatory signs of the eyelid margins or pouting of the orifices was published in 1980 by Korb and Henriquez.<sup>42</sup> The authors reported the presence and characteristics of MGD in symptomatic and asymptomatic contact lens wearers, whose eyelid margins were without significant inflammation or desquamation. Although corneal fluorescein staining was present in 57% of the symptomatic eyes compared with 10% of the asymptomatic controls, the majority of the orifices were found to be normal in appearance, without elevation, distension, depression, or surrounding signs of inflammation. They presented

histopathological data that when stagnation occurs, the duct dilates because of the accumulation of meibum and cellular debris that eventually may lead to atrophy of the gland. They also documented the occasional presence of polymorphonuclear leukocytes and lymphocytes within the expressed secretion in both the control group and the symptomatic group. Because obstruction and stagnation does not always manifest with pouting of the orifices or inflammation, the obstruction and subsequent MGD is often unapparent and may easily be missed (Fig. 2).

Histopathological investigations of MGD by both Gutgesell et al,<sup>44</sup> in 1982 in humans, and Gilbard et al,<sup>49</sup> in 1989 in rabbits, revealed meibomian gland inflammation to be a minimal contributor to MGD. In 2002, Obata<sup>50</sup> reported on the meibomian gland histopathology of 83 cadavers. Obata found that although the acini were frequently dilated with abnormal epithelia, there was no inflammatory cell infiltration. In 1991, Ong et al<sup>47</sup> reported the absence of observable clinical signs in MGD in humans, including inflammation or swelling of glands and elevation or depression of meibomian orifices, and therefore stressed that the diagnosis of MGD be primarily based on the appearance of expressed secretions. Finally, in 2002, based on his own findings and those of Shimazaki et al<sup>51</sup> and Lee and Tseng,<sup>52</sup> Goto et al<sup>53</sup> described a type of MGD that was characterized by minimal to no observable signs of inflammation of the meibomian glands of the lower eyelid in humans. Thus, there is a large body of knowledge from multiple researchers establishing that obvious inflammation may not be present with MGD.

### Nomenclature and Classification

Nomenclature and classification are presented to provide an understanding of how meibomian gland obstruction has been reported and classified and to highlight the scant attention directed to nonobvious meibomian gland obstruction. After the original description of the meibomian gland by Meibom,<sup>54</sup> many meibomian gland disorders have been described in the medical literature—ophthalmia tarsi,<sup>55</sup> conjunctivitis meibomiana,<sup>56</sup> meibomian seborrhea,<sup>57</sup> keratitis meibomian,<sup>58</sup> seborrheic blepharoconjunctivitis,<sup>40</sup> meibomitis,<sup>59</sup> meibomian keratoconjunctivitis,<sup>39</sup> and so on. The term “meibomian dysfunction” was introduced by McCulley and Sciallis<sup>41</sup> followed by the introduction of the term “meibomian gland dysfunction” by Korb and Henriquez.<sup>42</sup> MGD is now the most commonly accepted term for the spectrum of these disorders.

The bheparitis classification system of McCulley<sup>60</sup> in 1982 presented 7 major types of chronic blepharitis; 4 were described as anterior ciliary blepharitis (staphylococcal, seborrheic, mixed staphylococcal/seborrheic, and seborrheic with meibomian seborrhea), and the remaining 3 were termed posterior meibomitis [seborrheic with secondary meibomitis, primary meibomitis, other (atopic), and so on]. The term “blepharitis marginalis posterior” dates back to 1930,<sup>61</sup> whereas the term posterior meibomitis was introduced by McCulley et al<sup>60</sup> in 1982.

In 1991, Bron et al<sup>1</sup> suggested a classification system of MGD based on biomicroscopic morphological criteria. In the same year, Mathers et al<sup>62</sup> discussed the key role meibomian glands play in many of the conditions, which until then had



been classified as chronic blepharitis. In 1993, Mathers<sup>63</sup> reported 74% of the patients with chronic blepharitis had evidence of meibomian gland dropout and introduced the term obstructive MGD. In 1998, Bron and Tiffany<sup>64</sup> noted that meibomian gland disease and in particular, obstructive MGD, plays a vital role in the ocular surface disease. In 2002, Goto et al<sup>53</sup> introduced the term “noninflammatory obstructive MGD.” The authors propose that the term noninflammatory obstructive MGD might be better termed non obvious obstructive MGD (NOMGD) to convey more clearly that MGD may be present as the result of meibomian gland obstruction without obvious signs.

In 2003, Foulks and Bron<sup>4</sup> noted obstructive MGD to be the commonest form of MGD and subclassified it further into 2 forms, simple and cicatricial, which may also occur together. Foulks and Bron<sup>4</sup> reported that simple MGD is diagnosed by plugged orifices with cloudy or thickened secretion and that in cicatricial MGD, a scarring process in the marginal and tarsal mucosa causes exposure and retraction of the meibomian ductules and orifices into the marginal or tarsal conjunctiva.

Currently, the classification schemes for MGD generally include the 2 broad categories, hypersecretory and hyposecretory, with various subdivisions including obstructive, infective, cicatricial, seborrhic, and others. Although no one diagnostic classification system for MGD has been universally accepted, the existing classifications have provided a useful model for clinical use and should be used by the clinician when evaluating patients for dry eye, blepharitis, and ocular irritation.

Although the current classification systems include meibomian gland obstruction that is obvious upon examination, nonobvious meibomian gland obstruction has not been well classified.<sup>1,40,41,53</sup> Furthermore, because NOMGD can only be diagnosed by physical expression, NOMGD is likely frequently missed during clinical examination. Additional studies will be required to determine its precise prevalence.

### Clinical Diagnosis

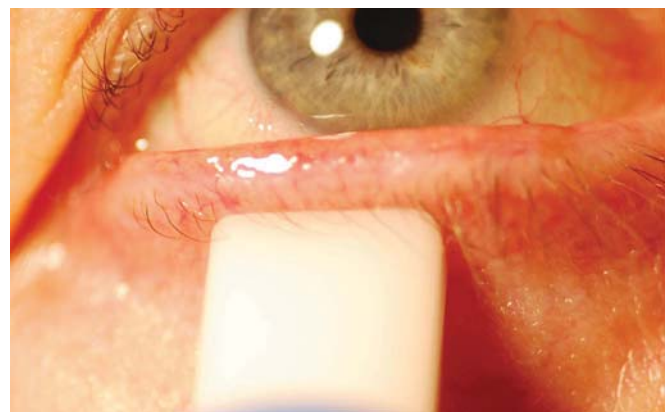As described in the prior section, clinical diagnosis of MGD has been directed primarily to overt signs of morphological changes of the eyelid margins and to the meibomian gland orifices. For example, slit-lamp examination of meibomian orifices in patients with obvious MGD may show the following: pouting (elevation overlying an orifice, probably representing an elevated internal plug of solidified secretions, which may be expressed from the orifice with pressure)<sup>4</sup>; capping (a dome of solidified oil over the orifices, released only by puncturing)<sup>4</sup>; ulceration of epithelialized orifice capping<sup>3</sup>; reduction in number of orifices and loss of definition of the orifice cuffs<sup>4</sup>; erythematous, irregular, thickened eyelid margins, with or without telangiectasia surrounding orifices; and serration of the eyelid margin.<sup>4</sup> In contrast, NOMGD may have none of the aforementioned obvious clinical signs observable with a slit lamp, rendering clinical diagnosis problematic (Figs. 1, 2).

Therefore, clinical evaluation of the meibomian glands requires a test of their expressibility. Several expression techniques, both for diagnosis and therapy, have been described, including the use of digital force on the outer eyelid surface

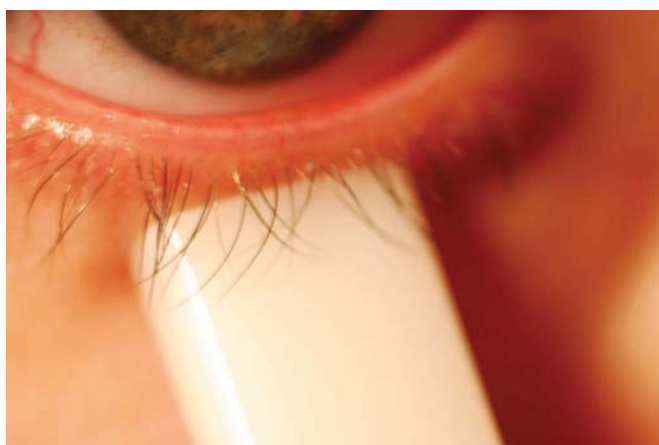near the eyelid margin,<sup>3,30,42,53,59,65–68</sup> the placement of an instrument, such as a sterile cotton-tipped applicator, behind the eyelid,<sup>42,69,70</sup> or the application of an instrument, such as a glass rod, speculum, or the Mastrotta paddle, to the outer or inner eyelid surface.<sup>1,67,70,71</sup> In contrast to therapeutic expression for relieving infective and/or purulent conditions, diagnostic expression may be used as a method to evaluate the “functionality” of individual or multiple meibomian glands (Figs. 1–7).

The pressure used for the expression of a meibomian gland and the characteristics of expressed secretions can be graded semiquantitatively. Shimazaki et al<sup>51,72</sup> used digital pressure as applied to the upper tarsus and the degree and ease of expression of meibomian secretions to grade the involvement: grade 0 (clear meibum easily expressed), grade 1 (cloudy meibum expressed with mild pressure), grade 2 (cloudy meibum expressed with more than moderate pressure), and grade 3 (meibum cannot be expressed even with strong pressure). Grade 0 and 1 were classified as normal. Another example of a semiquantitative grading scale was published by Sotozono et al,<sup>73</sup> who evaluated patients with Stevens–Johnson Syndrome and graded the secretions (but not the pressure used to express those secretions) to evaluate meibomian gland involvement. The nature of the meibomian gland secretion expressed manually at the center of the upper eyelid and was scored from 0 through 3, where 0 = clear oily fluid expressed, 1 = yellowish-white oily fluid expressed, 2 = thick cheesy material expressed, and 3 = inability to express any fluid from the meibomian glands. Grade 0 was considered normal.

The lack of a standardized technique for assessing meibomian gland expressibility makes both clinical diagnosis and the conducting of clinical studies highly subjective. Korb and Blackie<sup>74</sup> reported the use of a custom expression device, designed to mimic the force applied to the meibomian glands during a deliberate or forced blink.<sup>75,76</sup> The device has a flat

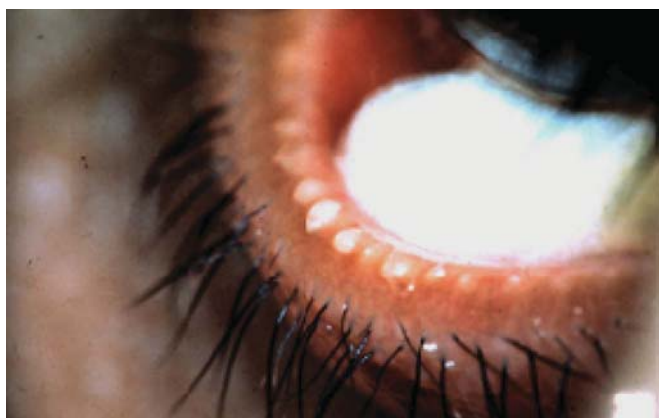

**FIGURE 3.** Obvious obstructive MGD with standardized diagnostic expression. The eyelid is slightly everted with 1.25 g/mm<sup>2</sup> pressure, applied slightly below the eyelashes. The eyelid, lashes, and eyelid margins evidence obvious inflammation. The meibomian glands do not release clear oil upon diagnostic expression, indicating that the glands are obstructed and would not be functional with the forces of deliberate blinking.

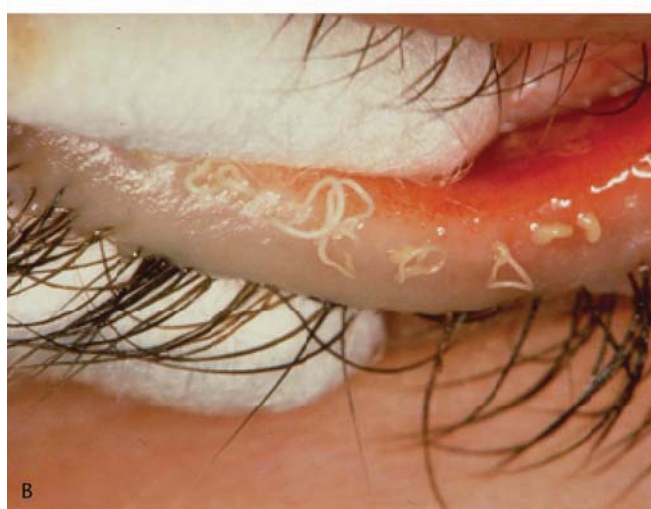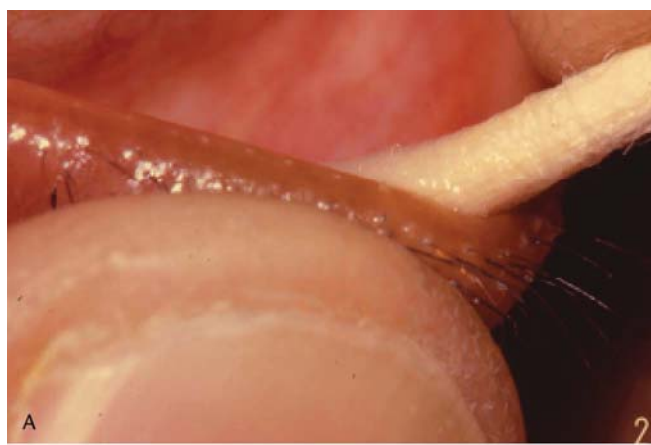


**FIGURE 4.** NOMGD with standardized diagnostic expression. The eyelid is slightly everted with 1.25 g/mm<sup>2</sup> pressure, applied slightly below the eyelashes. The eyelid, lashes, and eyelid margins are without inflammation or other pathological signs. The meibomian glands do not release any clear oil upon diagnostic expression, indicating that the glands are obstructed and would not be functional with the forces of deliberate blinking.

rectangular contact surface area of approximately 40 mm<sup>2</sup> with rounded edges; it applies a constant pressure, 1.25 g/mm<sup>2</sup>, to approximately one third of the external lower eyelid, allowing the simultaneous expression of approximately 8 meibomian glands (Figs. 3, 4). This pressure, 1.25 g/mm<sup>2</sup>, elevated the intraocular pressure from 12 to 18 mm Hg to approximately 35 mm Hg. Using this standardized pressure applied for a time of 10–15 seconds, they demonstrated significant correlation between dry eye symptoms and the number of meibomian



**FIGURE 5.** Obvious obstructive MGD with forceful expression. The eyelid and eyelid margin evidences obvious inflammation. The lower eyelid is compressed between a swab on the palpebral conjunctival surface and the thumb (or other firm instrument) on the outer eyelid surface. The amount of pressure required for forceful expression varies from 4 to 275 g/mm<sup>2</sup> (approximately 1.2–80 psi). This photograph illustrates that expression with adequate force may express copious amounts of inspissated secretion. The secretion may be white or purulent.

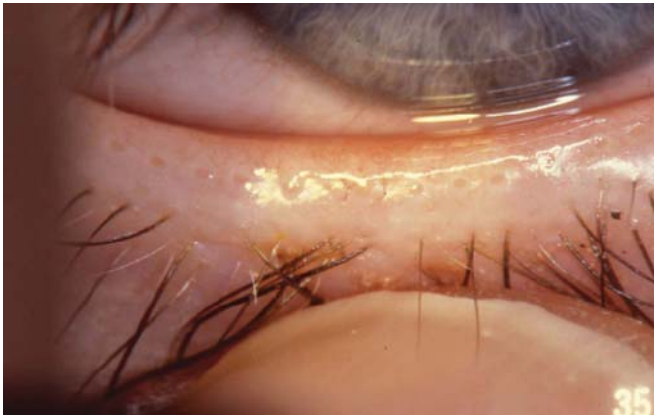


**FIGURE 6.** A, NOMGD with recalcitrant obstruction despite forceful expression. The lower eyelid is compressed between a swab on the palpebral conjunctival surface and the thumb on the outer eyelid surface. Despite the use of maximum force approaching 275 g/mm<sup>2</sup> (approximately 80 psi), the glands do not yield significant secretion. Before the application of forceful expression, the lids, eyelid margins, and meibomian gland orifices appeared normal. However, with forceful expression, the orifices evidenced elevated whitish plugs. B, NOMGD yielding secretion with forceful expression. The lower eyelid is compressed between 2 swabs on the surface of the palpebral conjunctiva and on the outer eyelid surface. Before expression, the lids, eyelid margins, and orifices appeared normal; however, standardized diagnostic expression failed to express secretion. The application of forceful expression almost immediately produced copious secretion on the form of filaments, indicating narrowing of the distal portion of the ducts, near the orifice. The color of the secretion varied from white to semipurulent.

glands yielding liquid secretion. The instrument, if made commercially available, is expected to provide the clinician and researcher with a standardized method of assessing meibomian gland functionality.

Additionally, the line of Marx has become of interest in the diagnosis of MGD. Vital staining with fluorescein, lissamine green, and rose bengal has been used to determine





**FIGURE 7.** Optimal eyelid without MGD, yielding clear oil with diagnostic expression. The eyelid is slightly everted outward with minimal digital pressure, applied slightly below the eyelashes. The eyelid, lashes, and eyelid margins are without inflammation or other pathological signs. Upon the application of minimal pressure of 1–2 g/mm<sup>2</sup> (approximately 0.3–0.6 psi), the meibomian glands release clear oil. This is the ideal finding indicating meibomian gland functionality.

the position of the meibomian gland orifices as related to the position of the mucocutaneous junction,<sup>77,78</sup> and the characteristics of the line of Marx have been suggested to be a clinical tool for rapid assessment of MGD.<sup>79</sup> Yamaguchi et al<sup>79</sup> suggested that the location of the line of Marx indicates meibomian gland functionality; the location of the line of Marx on the ocular side of the meibomian gland orifices indicates normal function, and on the cutaneous side it indicates MGD. Norn et al<sup>80</sup> demonstrated that with aging, the line of Marx becomes more irregular and shifts anteriorly toward the cutaneous side of the meibomian orifices.

Symptoms are not usually present in milder forms of MGD<sup>4</sup> unless the integrity of the tear film is stressed, for instance, by contact lens use,<sup>81</sup> prolonged use of video display terminals,<sup>82</sup> or a dramatic change in the humidity or temperature of the environment.<sup>83</sup> Thus, patients with an apparently “normal” eye may unexpectedly manifest contact lens intolerance or report dry eye symptoms after prolonged use of computers or other challenging environments. When present, symptoms frequently do not correlate with signs of the disease seen on examination.<sup>3,84</sup> The patient usually has nonspecific symptoms, often similar to those of aqueous-deficient dry eye (ADDE) such as burning, redness, irritation, grittiness, itching, dry eye sensation, ocular fatigue, pain, and fluctuating vision.<sup>3,5</sup> In the authors’ experience, many patients with NOMGD present with severe symptoms, a history of consultations with multiple physicians, but had no relief from treatment. Examination may reveal no positive signs of dry eye, for example, reduced BUT, corneal/conjunctival staining, eyelid wiper epitheliopathy, and so on. In addition, the eyelid margins and meibomian glands may not present significant findings, and thus MGD would not be expected. A possible clue is the self-report of difficulty in maintaining clear vision and the need to blink frequently. Excess blinking should suggest nonobvious NOMGD because forceful blinking may

express meibomian gland secretion thus improving the tear film and vision.<sup>16,85–87</sup>

It is also thought that commonly used visual acuity measurements (eg, Snellen acuity) do not represent the actual visual experience in daily life such as while reading, driving, working at video display terminals, and so on. To measure functional vision, visual acuity is measured after sustained eye opening without blinking for 10–20 seconds and is referred to as “functional visual acuity.”<sup>87,88</sup> However, there is no accepted clinical procedure to measure the effect of MGD on habitual visual acuity.

In summary, clinical diagnosis of NOMGD is dependent on physical expression. Martin et al<sup>89</sup> reported that “an old ophthalmology axiom states that the external exam is not completed until all 4 eyelids have been massaged for meibomian secretions and the lids everted.” This axiom seems particularly relevant for NOMGD.

### Complementary Roles of the Aqueous and Lipid Layer

Mathers<sup>63</sup> noted that the normal basal tear flow rate was similar in patients with and without dry eyes (0.35  $\mu$ L/min), but the tear loss because of evaporation was increased in patients with dry eye. He suggested that if evaporation could be controlled and returned to normal levels in patients with low tear flow, the eye might be able to maintain a healthier tear osmolarity despite the low flow. Subsequently, Mathers et al<sup>90</sup> found that meibomian gland expression increased lipid layer thickness and significantly decreased evaporation, demonstrating the complementary functions of the lipid and aqueous components.

The aqueous phase of the tear film is also important for an adequate spreading of the meibomian secretion over the tear film. Goto et al<sup>53</sup> found that whereas forced blinking decreased tear evaporation in eyes with MGD and without aqueous tear deficiency (ATD), no significant change of tear evaporation was observed with forced blinking in eyes with both MGD and ATD. Goto and Tseng<sup>91</sup> later studied the dynamic tear film interference pattern in eyes with ATD and found that the spreading of the lipid layer is irregular and the stabilization of the lipid layer thickness takes longer in eyes with ATD than for normal eyes. Therefore, interference patterns improved after the patients underwent punctal occlusion. Further support for the complementary role of the aqueous layer in supporting the lipid layer was provided by Korb et al<sup>92</sup> who showed a significant increase in the lipid layer after just 5 minutes of exposure to 100% periocular humidity. Thus, although the aqueous and lipid layers are perceived as independent in diagnosing the primary cause of dry eye, they are closely related with each affecting the other. This concept was highlighted in a recent review by Bron et al<sup>93</sup> where the authors hypothesized that despite the primary causes of EDE or ADDE, they are not mutually exclusive, and with advancing dry eye disease, ADDE takes on the factors of EDE and vice versa.

### Other Factors

Because many factors have been reported in connection with MGD, the possible relevance of these factors to nonobvious MGD is briefly reviewed. Bacteria on the eyelid,

margins and within the glands including *S. aureus*, coagulase-negative staphylococci, and *Propionibacterium acnes* are the most common commensals found on the eyelid, and all produce bacterial lipolytic exoenzymes, such as triglyceride lipase, fatty wax, and cholesteryl esterases.<sup>60,94,95</sup> These enzymes can break the normal meibum complex lipids into potentially inflammatory free fatty acid fragments. In addition, the cholesterol produced by the cholesterol esters provides a substrate for other bacteria to grow.<sup>96</sup> However, the relevance of eyelid bacteria, these enzymes, and their by-products to nonobvious MGD is not established.

Additionally, changes in the composition of aqueous tears also contribute to the pathogenesis and manifestations of MGD. Yamada et al<sup>33</sup> have shown that the tear concentration of tear protein lipocalin (tear specific prealbumin) is decreased in patients with MGD. This protein plays an important role in the interaction of the aqueous and lipid components of the tear film. These changes are evidence of the complexity of the multifactorial nature of the relationship between the lipid and aqueous components of the tear film. However, their relevance to nonobvious MGD is not established.

Not surprisingly, measurable changes to the inflammatory profile of the ocular surface as a result of MGD have been documented. Barton et al<sup>97</sup> reported an increased concentration of the proinflammatory cytokine interleukin-1 alpha (IL-1 $\alpha$ ) in patients with MGD. Solomon et al,<sup>98</sup> using immunofluorescent staining, detected elevated expression of conjunctival markers of inflammation and the presence of proinflammatory mediators in the tear film of patients with MGD. Increased protease activity on the ocular surface was postulated to be 1 mechanism by which precursor IL-1 beta is cleaved to the mature biologically active form. Afonso et al<sup>99</sup> and Macri and Pflugfelder<sup>100</sup> have reported that tear production may be reduced and tear clearance decreased in meibomian gland disease, both of which may contribute toward increased concentration of proinflammatory cytokines, leading to ocular surface inflammation and presenting clinically as symptoms of ocular irritation. Because nonobvious MGD results in compromise to the tear film and ocular lubrication, inflammation of the ocular surface may be a result of NOMGD.

Despite the potentially coexisting roles of bacteria, tear film osmolarity, and inflammation, it is critical to recognize that the primary mechanism for obstructive MGD is keratinization of the meibomian gland ducts.<sup>40,42,44,47,50</sup> Thus, the success of any therapy for all forms of obstructive MGD is primarily dependent upon relief of the obstruction and secondarily upon the management of other factors such as inflammation and/or infection.

## Treatment

Treatments for any form of MGD may also be the treatment for NOMGD. Therefore, contemporary treatments will be reviewed while highlighting which of these treatments have particular relevance to the management of NOMGD. Treatment of NOMGD is designed to restore the normal flow of meibomian gland secretions, thereby increasing the likelihood of a healthy lipid layer and consequently enhancing tear film stability. This outcome is achieved primarily through

removal of the obstruction, and apparent subsequent upregulation of the secretion. The 4 main treatment approaches for MGD are as follows: (1) physical expression to relieve the obstruction (Figs. 5, 6A, B), (2) administration of heat to the eyelids to potentially liquify solidified meibomian gland contents, (3) eyelid scrubs to relieve external meibomian gland orifice blockage, and (4) medications to mitigate infection and inflammation of the eyelids.

Physical expression of meibomian glands for therapeutic purposes is an in-office procedure, with at least an 80-year history,<sup>40,41,67,101</sup> which can be supplemented by the patient performing self-expression at home.<sup>41</sup> The reported techniques vary from gently massaging the eyelids against the eyeball<sup>41</sup> to forceful squeezing of the eyelids either against each other<sup>39</sup> or between a rigid object on the inner eyelid surface and a finger, thumb, or rigid object (glass rod, swab, metal paddle, and so on) on the outer eyelid surface.<sup>39,42,59,67,71</sup> The purpose of the rigid object on the inner eyelid surface is to protect the eyeball from forces transferred through the eyelid and also to offer a stable resistance to increase the amount of force that can be applied to the glands. The amount of force needed to express obstructed glands can be significant. The authors have measured this force as up to 250 g/mm<sup>2</sup> (approximately 75 psi, unpublished data, January 2008–May 2009). The amount of pain increases rapidly as the force of expression exceeds 15 g/mm<sup>2</sup> (approximately 5 psi). Forces of 80 g/mm<sup>2</sup> (approximately 25 psi) and greater, frequently producing excruciating pain, thus considerably limiting clinical application. Regardless of the method of meibomian gland physical expression, the goal is to express the obstruction and other meibomian gland material from the gland, thereby removing obstruction and allowing gland secretion. Treatment with physical expression should be continued until the dysfunction is resolved.<sup>39</sup> It is important to emphasize that in contrast to the significant amount of force required for therapeutic expression to relieve meibomian gland obstruction (up to 250 g/mm<sup>2</sup>), the force for diagnostic expression to determine meibomian gland functionality should simulate the natural expression force of a deliberate blink (1–2 g/mm<sup>2</sup>).<sup>75</sup>

Warm compresses have been the traditional method for the administration of heat to the eyelid. However, many innovative devices, with the goal of providing a regulated elevated temperature to the eyelids, have been reported. These devices, in the forms of a face mask, goggles, or similar device,<sup>12,102–107</sup> have been designed to more effectively heat the eyelids and increase convenience for the patient, possibly improving compliance. Mori et al<sup>102</sup> have used an infrared warming device and a disposable heating device,<sup>103</sup> which uses oxidation of iron for producing heat. Using these devices to apply heat, the authors have documented an increase in lipid layer thickness and BUT and improvement in dry eye symptoms. Goto et al<sup>12</sup> also studied the use of an infrared warming device and demonstrated that the regular use for 2 weeks results in an improvement in subjective discomfort score, tear evaporation rate, fluorescein staining, rose bengal staining, BUT, and meibomian gland orifice obstruction. Similarly, Matsumoto et al<sup>104</sup> demonstrated a warm moist air device to improve tear stability and provide symptomatic relief in patients with MGD. However, these devices do not seem to

be widely used, and warm compresses remain the mainstay of home therapy.

Regardless of methodology, the therapeutic goals of heat therapy are as follows: (1) to heat the meibomian gland contents to facilitate their secretion into the tear film, (2) to alleviate meibomian gland obstruction, and (3) to increase vascular flow to the tissue surrounding the meibomian glands.<sup>108</sup> Although there is no single melting point for solidified meibomian secretion<sup>30,85,109</sup> because the chemistry and viscosity of the solidified secretion itself are variable,<sup>13,18,30,84,110,111</sup> we do know that solidified secretions from severely obstructed glands have a considerably higher melting point than those from apparently normal unobstructed glands.<sup>30,106,110,112</sup> Thus, it can be assumed that higher temperatures, provided safety is maintained, are superior for the treatment of more severely obstructed glands.

Despite the benefits of heat therapy, there are some limitations to its efficacy. For example, heat transfer between the outer and inner eyelid surfaces is inefficient because the vascular network carries heat away from the tissues and the eyelid tissue itself has insulating properties.<sup>108,113</sup> Despite this loss of heat, treatment success has been reported by Olson et al<sup>114</sup> and Mitra et al<sup>106</sup> who both demonstrated an increase in tear film lipid layer thickness after the administration of heat to the eyelids. Nagymihalyi et al<sup>115</sup> performed meibometry before and after heat therapy and demonstrated that the rate of lipid delivery is increased with heat therapy.

The application of pressure during heating would increase the rate of heat transfer between the outer and the inner eyelid surfaces because it would decrease the rate of blood flow and thus decrease the removal of heat via the vasculature.<sup>113</sup> However, Solomon et al<sup>116</sup> have shown that heat applied during warm compress application, even when pressure is gentle, frequently alters the physical properties of the cornea as evidenced by the polygonal reflex of Fischer-Schweitzer, resulting in a transient visual blur. Therefore, application of direct pressure to the eyelids in an unsupervised home therapy may not be advisable.<sup>108</sup> Lemp et al<sup>117</sup> presented a device using a novel application of thermodynamic energy to remove meibomian gland obstructions and thus reactivate the meibomian glands. The study reported that the device was successful in alleviating symptoms, increasing lipid layer thickness, and restoring the ability of the meibomian glands to secrete.

Eyelid scrubs, although primarily suggested for anterior blepharitis, can help remove crusts and inspissated secretions blocking the gland orifices. Eyelid scrubs are performed on the eyelid margin over the meibomian gland orifices to prevent obstructive overgrowth of material from sealing the orifice.<sup>42</sup> Use of eyelid scrubs and eyelid massage has also been shown to improve tear film BUT.<sup>118</sup> Eyelid hygiene also helps and is the universal treatment for any associated staphylococcal or seborrheic blepharitis.<sup>1,4,13</sup> Therefore, use of eyelid scrubs has been suggested as part of the daily routine of heat therapy and eyelid massage in patients with MGD.<sup>42,118</sup>

Antibiotics, particularly the tetracyclines, including doxycycline, tetracycline, and minocycline, continue to find a place in the modern management of MGD. Tetracyclines decrease the secretion of bacterial lipases, which are known to

break down the normal meibum lipids into inflammatory free fatty acid fragments.<sup>119,120</sup> Tetracyclines are also related to anticollagenase and anti-matrix metalloproteinase (MMP) properties.<sup>119,121,122</sup> Because these functions are concentration dependent, systemically administered tetracyclines were understood to be secreted in optimal concentration into the tear film. However, Smith et al<sup>123</sup> did not detect any doxycycline in the tear film of patients undergoing treatment, despite finding a reduction in the amount of MMP-9 protein, indicating that doxycycline may have a different mechanism of action than direct inhibition of MMP activity or the synthesis of IL-1 from corneal epithelial cells. Recently, Souchier et al<sup>124</sup> reported the success of minocycline in decreasing isoC20, a branch chain fatty acid, levels to its normal values and resulting in an increase in BUT after 2 months of minocycline therapy in patients with MGD. Although the involved mechanisms may be different than what we currently understand, systemic tetracyclines do seem to improve the lipid profile of meibomian gland secretion.

It has also been noted that a systemic concentration of tetracyclines lower than the minimum inhibitory concentration can inhibit the bacterial production of lipases, possibly explaining Yoo et al's<sup>125</sup> observations that even a low dose of doxycycline is as beneficial and is better tolerated than a full dose of tetracycline or doxycycline. Similar to the anti-inflammatory properties of tetracyclines, macrolides also have anti-inflammatory and anti-MMP activity<sup>126</sup> and are being investigated for a possible role in the management of MGD when applied topically.

A recent study examined the use of a topical macrolide antibiotic, azithromycin (1%).<sup>127</sup> The drug treatment efficacy was tested on a group of subjects with posterior blepharitis. The results were encouraging, showing a significant improvement in meibomian gland secretion quality, eyelid redness, and overall symptomatic relief. The study also reported an improvement in the meibomian gland "plugging" score. The "plug" in this context referred to the quality of secretion (clear secretion vs. turbid secretion) that was easily observable in the meibomian gland orifices in the central third of the eyelid. (There is no mention of expression or the expression technique).

Although there is evidence that antibiotics may improve patient symptoms and improve meibomian gland lipid secretion quality, there is no evidence that antibiotics can relieve meibomian gland obstruction. This suggests that the improvements may not be in functional restoration of obstructed meibomian glands but in the improvement of the quality of meibomian gland secretions for those meibomian glands without significant obstruction. If the latter is correct, antibiotic therapy may be very beneficial if administered in combination with, or immediately after, treatment to remove the meibomian gland obstruction (physical expression, heat therapy, and so on).

The use of topical cyclosporine, an immunosuppressant, in ADDE (especially with ocular surface inflammation) is now well established.<sup>128,129</sup> Although there is supporting evidence, the role of topical cyclosporine in MGD is not clearly established. Perry et al<sup>128</sup> studied the effect of cyclosporine 0.05% eyedrops in patients of MGD and noted an



improvement in objective signs; however, there was no significant improvement in subjective symptoms. In contrast, Rubin and Rao<sup>129</sup> showed an improvement in symptoms and objective signs such as eyelid telangiectasia, ocular surface staining, and tear BUT with the use of cyclosporine in patients with MGD. The addition of topical cyclosporine can also benefit the patient by treating any associated aqueous deficiency. Thus, if the obstruction is first removed via heat therapy and physical expression, topical cyclosporine may then help alleviate any associated inflammatory components.

The administration of topical corticosteroids to suppress the inflammatory response associated with dry eye has been shown to be effective in the relief of dry eye signs, reduction in ocular surface staining,<sup>130–132</sup> reduction of eyelid wiper epitheliopathy,<sup>133</sup> and dry eye symptoms.<sup>130–132</sup> The use of steroids is usually temporary or pulsatile because of the potential risks of chronic use; additionally, the obstruction would first have to be removed from the glands, in conjunction with steroid use, to increase the likelihood of treatment success.

Meibomian glands have androgen receptors similar to other sebaceous glands in the body, and androgen deficiency, insensitivity, and antiandrogen therapy have been shown to have detrimental effect on the functioning of meibomian glands.<sup>134,135</sup> Because systemic androgens are associated with significant side effects, topical androgens are being evaluated as a possible therapeutic option for patients with MGD,<sup>134,135</sup> and further research is expected to better elucidate such a role.

Because patients with MGD have an altered lipid composition, changing the dietary lipid intake may theoretically affect the lipid composition of the meibomian glands. Omega-3 and omega-6 essential fatty acid supplements have been recommended as treatments.<sup>136</sup> However, symptomatic improvement observed with such supplements is not attributed to antiinflammatory and antikeratinizing effects<sup>136</sup> but rather to a change in meibomian lipid composition.

The most common tear substitutes involve aqueous/mucin analogues and, in patients with MGD, perform a palliative function to maintain the health of the ocular surface and alleviate patient symptoms. Apart from alleviating the symptoms, the tear substitutes may facilitate adequate spreading of the meibomian gland secretions over the entire ocular surface.<sup>91</sup> Use of hypotonic tear supplements has been suggested to compensate for the increased hypertonicity of the tears in patients with dry eye.<sup>137,138</sup> Gilbard et al<sup>137,138</sup> report that increased hypertonicity can damage the ocular surface cells resulting from an average osmolarity increase of 41 mOsm/L over the normal value of 302 mOsm/L.

A newer class of tear substitutes involves the use of emulsions containing lipids. Korb et al<sup>139</sup> have demonstrated the use of a lipid containing metastable oil-in-water emulsion eyedrops, which dissociates upon delivery to the tear film. More recently, Scaffidi and Korb<sup>140</sup> reported that commercially available lipid containing metastable oil-in-water emulsion eyedrops have a measurable beneficial effect on the lipid layer thickness, which almost doubled with use of these drops. Other studies examining the benefits of emulsion drops have reported significant improvements in tear stability, patient comfort, and lipid layer thickness.<sup>141,142</sup> A recently introduced cationic emulsion eye drop<sup>143</sup> reportedly combines

“lubricating and hydrating” components to facilitate optimal tear spreading, replenishment of the lipid layer, and slowing of tear evaporation. The application of ointment to the eyelid margins is reported to provide a reservoir of lipid on the eyelid to replenish the tear film lipids upon blinking but frequently also results in transient blur.<sup>53</sup>

Environmental modifications also help in the therapy of these patients. Exposure to conditions of low relative humidity such as deserts, aircraft cabins, and temperature-controlled heated or air-conditioned environments increase evaporative tear loss. Avoidance of such conditions may reduce evaporative loss of tears and is essential and aid the avoidance of dry eye symptoms and reducing the need for tear substitutes.

Maskin,<sup>144</sup> in 2009, reported a reduction in the inflammatory signs of obstructive MGD as a result of intraductal meibomian gland probing. All patients who received this novel treatment exhibited signs of eyelid inflammation before the intraductal meibomian gland probing treatment; however, no data were provided for the diagnostic methods used to determine either the obstruction or the severity of MGD. Although the population treated in that study all exhibited obvious inflammatory signs with apparent meibomian gland obstruction, this novel procedure may also have application for the treatment of NOMGD, assuming it is shown to be safe and effective.

Thus, despite the numerous possible treatment options for MGD, obstructive MGD requires relief of the obstruction by liquification and/or physical expression of the obstruction. The latter is particularly important for NOMGD because the other factors such as inflammation and/or infection may not be clinically detectable.

## DISCUSSION

Although the term NOMGD might seem to be only 1 more addition to the various classifications of the various forms of MGD, it is an essential term to convey and emphasize that MGD may be present not only without inflammation but also without other obvious signs. There is increasing evidence that the form of MGD, referred to NOMGD in this review, may be the leading cause of EDE.<sup>12,145</sup> Furthermore, the recognition of NOMGD may be particularly important in providing potential insight and direction for the current conundrum of the inability to cure many cases of dry eye and even more importantly to prevent some cases of dry eye. The authors believe that the majority of dry eye has its genesis in NOMGD. In addition, because of the current environmental challenges such as significant near work demands and ever increasing use of visual display terminals, it is reasonable to hypothesize that this condition may start at a young age and, in its incipient stages, is asymptomatic. If NOMGD is a precursor to obvious obstructive MGD, the ability to diagnosis and treat this obstructive dysfunction in its early nonobvious stages is critically important for decreasing the prevalence and severity of EDE disease in later years. As such, further research is required to understand the development of NOMGD.

MGD has traditionally been reported to present with any 1 or a combination of the hallmark signs of infection and inflammation of the surrounding tissue and the meibomian

glands themselves (Figs. 1, 3, 5). Thus, MGD has been considered a disorder with obvious and readily observed signs and frequently considered synonymous with posterior blepharitis. These concepts remain the contemporary understanding of MGD. However, the nomenclature of posterior blepharitis, by definition, conveys the presence of significant inflammation. Thus, in view of our current understanding of obstructive MGD, posterior blepharitis should not be a synonym for MGD because obvious inflammation does not occur with all the variations of obstructive and NOMGD.

The lack of obvious clinical signs accompanying NOMGD renders the clinical diagnosis problematic (Figs. 2, 4, 6). There are multiple reasons why obstructive MGD may not be detected. If there are no obvious eyelid or meibomian gland orifice changes, obstruction would not be expected and could not be detected without diagnostic expression. Even when eyelid changes such as serration of the eyelid margins or mild inflammation of the eyelid margin are present, if there are no coexisting significant meibomian gland orifice changes, obstruction might not be expected. It is only if the meibomian gland orifices evidence changes such as pouting, protruding plugs, recession, or surrounding inflammation that MGD and/or meibomian gland obstruction would normally be suspected. Expression of the gland is therefore vital for diagnosis, but the application and amount of pressure for diagnostic expression requires standardization if the technique is to be reliably diagnostic and valid.<sup>74</sup> A diagnostic expression device and the first standardized expression data have been reported.<sup>74</sup>

## SUMMARY AND CONCLUSIONS

In the final chapter of the 2007 International Dry Eye Workshop Report,<sup>6</sup> specific topics for future research were defined as important to better understand the link between meibomian gland function and dry eye disease. For example, (1) identify the number of meibomian glands necessary to provide an adequate lipid layer for tear film function, (2) perform comprehensive qualitative and quantitative evaluation of meibomian gland secretions in healthy subjects versus subjects with dry eye, (3) identify key nutritional components for optimal meibomian gland function, (4) identify the role of meibomian gland function and lubrication, and (5) identify the key steps in the obstruction process with particular attention to keratinization and hyperkeratinization of the meibomian gland ducts. This selection of topics clearly indicates the extent to which we do not understand the complex role of meibomian gland function in the development of dry eye. Furthermore, the significant focus on the roles of meibomian gland obstruction and secretion quality in contrast to the emphasis on infection reflects the paradigm shift in the conceptualization of MGD and the direction of ongoing research.

Finally, the recognition that NOMGD is a significant and apparently ubiquitous factor across the spectrum of dry eye, from the extremes of mild transient symptoms to severe dry eye disease, will further accelerate research in the diagnosis, treatment, and prevention of all forms of obstructive MGD. Although many questions remain to be answered, the authors are confident that this recent recognition of the importance of NOMGD will not only accelerate research but also result in the

inclusion of an evaluation for NOMGD whenever signs or symptoms of dry eye disease are present. We predict that such a test will become as commonplace as tear film stability and ocular staining tests are, as basic diagnostic tools, in the clinical evaluation of dry eye. Recognition of the importance of nonobvious meibomian gland obstruction is a key step for both clinical practice and research direction to further develop the diagnosis, management, and ultimately the prevention of dry eye disease.

## REFERENCES

- Bron AJ, Benjamin L, Snibson GR. Meibomian gland disease. Classification and grading of lid changes. *Eye*. 1991;5(pt 4):395–411.
- Tiffany JM. Physiological functions of the meibomian glands. *Prog Retin Eye Res*. 1995;14:47–74.
- Driver PJ, Lemp MA. Meibomian gland dysfunction. *Surv Ophthalmol*. 1996;40:343–367.
- Foulks GN, Bron AJ. Meibomian gland dysfunction: a clinical scheme for description, diagnosis, classification, and grading. *Ocul Surf*. 2003;1:107–126.
- Bron AJ, Tiffany JM. The contribution of meibomian disease to dry eye. *Ocul Surf*. 2004;2:149–165.
- Lemp MA, Baudouin C, Baun J. The definition and classification of dry eye disease: report of the Definition and Classification Subcommittee of the International Dry Eye Workshop. *Ocul Surf*. 2007;5:75–92.
- Kroll MW, Efimov IR, Tchou PJ. Present understanding of shock polarity for internal defibrillation: the obvious and non-obvious clinical implications. *Pacing Clin Electrophysiol*. 2006;29:885–891.
- Leizerovich GS, Taranukha NA. Nonobvious features of dynamics of circular cylindrical shells. *Mech Solids*. 2008;43:246–253.
- Cherkasov A, Jones SJM. An approach to large scale identification of non-obvious structural similarities between proteins. *BMC Bioinformatics*. 2004;5:1–11.
- Pennazio M, Arrigoni A, Rocci MP, et al. Does jejunoscscopy improve the diagnostic yield in patients with diarrhea and/or malabsorption of non-obvious origin. *Gastroenterology*. 1995;108(Suppl):A313.
- Victory P, Alvarezlarena A, Germain G, et al. A non-obvious reaction pathway in the formation of 2-aminobenzene-1,3-dicarbonitriles from alpha, beta-unsaturated ketones or aldehydes. *Tetrahedron*. 1995;51:253–242.
- Goto E, Monden Y, Takano Y, et al. Treatment of non-inflamed obstructive meibomian gland dysfunction by an infrared warm compression device. *Br J Ophthalmol*. 2002;86:1403–1407.
- Bron AJ, Tiffany JM, Gouveia SM, et al. Functional aspects of the tear film lipid layer. *Exp Eye Res*. 2004;78:347–360.
- Lemp MA, Nichols KK. Blepharitis in the United States 2009: a survey based perspective on prevalence and treatment. *Ocul Surf*. 2009;7(Suppl):S1–S22.
- TFOS Newsletter. September 2008.
- Wolff E. The muco-cutaneous junction of the lid-margin and the distribution of the tear fluid. *Trans Ophthalmol Soc U K*. 1946;66:291–308.
- Weingeist TA. Fine structure and function of ocular tissues. The glands of the ocular adnexa. *Int Ophthalmol Clin*. 1973;13:243–261.
- Jester JV, Nicolaides N, Kiss-Palvolgyi I, et al. Meibomian gland dysfunction. II. The role of keratinization in a rabbit model of MGD. *Invest Ophthalmol Vis Sci*. 1989;30:936–945.
- Tiffany JM. Individual variations in human meibomian lipid composition. *Exp Eye Res*. 1978;27:289–300.
- Tiffany JM. The role of meibomian secretion in the tears. *Trans Ophthalmol Soc U K*. 1985;104(pt 4):396–401.
- Tiffany JM. The lipid secretion of the meibomian glands. *Adv Lipid Res*. 1987;22:1–62.
- Nicolaides N, Kaitaranta JK, Rawdah TN, et al. Meibomian gland studies: comparison of steer and human lipids. *Invest Ophthalmol Vis Sci*. 1981;20:522–536.
- Nicolaides N. Recent findings on the chemical composition of the lipids of steer and human meibomian glands. In: Holly EJ, ed. *The Preocular Tear Film In Health, Disease and Contact Lens Wear*. Lubbock, TX: Dry Eye Institute; 1986:570–596.

24. Nicolaides N, Santos EC, Smith RE, et al. Meibomian gland dysfunction. III. Meibomian gland lipids. *Invest Ophthalmol Vis Sci.* 1989;30:946–951.
25. Shine WE, McCulley JR. Polar lipids in human meibomian gland secretions. *Curr Eye Res.* 2003;26:89–94.
26. Shine WE, McCulley JR. Meibomianitis: polar lipid abnormalities. *Cornea.* 2004;23:781–783.
27. Nichols KK, Ham BM, Nichols JJ. Identification of fatty acids and fatty acid amides in human meibomian gland secretions. *Invest Ophthalmol Vis Sci.* 2007;48:34–39.
28. Butovich IA, Millar TJ, Ham BM. Understanding and analyzing meibomian lipids—a review. *Curr Eye Res.* 2008;33:405–420.
29. Tiffany JM, Marsden RG. The influence of composition on physical properties of meibomian secretion. In: Holly EJ, ed. *The Preocular Tear Film In Health, Disease and Contact Lens Wear.* Lubbock, TX: Dry Eye Institute; 1986:597–608.
30. Ong BL, Larke JR. Meibomian gland dysfunction: some clinical, biochemical and physical observations. *Ophthalmic Physiol Opt.* 1990;10:144–148.
31. Sullivan DA, Rocha EM, Ullman MD, et al. Androgen regulation of the meibomian gland. *Adv Exp Med Biol.* 1998;438:327–331.
32. Sullivan DA, Yamagami H, Liu M, et al. Sex steroids, the meibomian gland and evaporative dry eye. *Adv Exp Med Biol.* 2002;506(pt A):389–399.
33. Yamada M, Mochizuki H, Kawai M, et al. Decreased tear lipocalin concentration in patients with meibomian gland dysfunction. *Br J Ophthalmol.* 2005;89:803–805.
34. Millar TJ, Mudgil P, Butovich IA, et al. Adsorption of human tear lipocalin to human meibomian lipid films. *Invest Ophthalmol Vis Sci.* 2009;50:140–151.
35. Mishima S, Maurice DM. The oily layer of the tear film and evaporation from the corneal surface. *Exp Eye Res.* 1961;1:39–45.
36. Holly FJ. Physical chemistry of the normal and disordered tear film. *Trans Ophthalmol Soc U K.* 1985;104(pt 4):374–380.
37. Lemp MA, Holly FJ, Iwata S, et al. The precorneal tear film. I. Factors in spreading and maintaining a continuous tear film over the corneal surface. *Arch Ophthalmol.* 1970;83:89–94.
38. Fuchs E. *Text-Book of Ophthalmology.* Philadelphia, PA: JB Lippincott; 1917.
39. Duke-Elder WS, MacFaul PA. The ocular adnexa, part II. Diseases of the eyelids. In: Duke-Elder WS, MacFaul PA, eds. *System of Ophthalmology.* Vol XIII. London, United Kingdom: H. Kimpton; 1974:241.
40. Keith CG. Seborrhoeic blepharo-kerato-conjunctivitis. *Trans Ophthalmol Soc U K.* 1967;87:85–103.
41. McCulley JP, Sciallis GF. Meibomian keratoconjunctivitis. *Am J Ophthalmol.* 1977;84:788–793.
42. Korb DR, Henriquez AS. Meibomian gland dysfunction and contact lens intolerance. *J Am Optom Assoc.* 1980;51:243–251.
43. Jester JV, Nicolaides N, Smith RE. Meibomian gland studies: histologic and ultrastructural investigations. *Invest Ophthalmol Vis Sci.* 1981;20:537–547.
44. Gutgesell VJ, Stern GA, Hood CI. Histopathology of meibomian gland dysfunction. *Am J Ophthalmol.* 1982;94:383–387.
45. Straatsma BR. Cystic degeneration of the meibomian glands. *AMA Arch Ophthalmol.* 1959;61:918–927.
46. Robin JB, Jester JV, Nobe J, et al. In vivo transillumination biomicroscopy and photography of meibomian gland dysfunction. A clinical study. *Ophthalmology.* 1985;92:1423–1426.
47. Ong BL, Hodson SA, Wigham T, et al. Evidence for keratin proteins in normal and abnormal human meibomian fluids. *Curr Eye Res.* 1991;10:1113–1119.
48. Seal DV, McGill JJ, Jacobs P, et al. Microbial and immunological investigations of chronic non-ulcerative blepharitis and meibomianitis. *Br J Ophthalmol.* 1985;69:604–611.
49. Gilbard JP, Rossi SR, Heyda KG. Tear film and ocular surface changes after closure of the meibomian gland orifices in the rabbit. *Ophthalmology.* 1989;96:1180–1186.
50. Obata H. Anatomy and histopathology of human meibomian gland. *Cornea.* 2002;21(Suppl 7):S70–S74.
51. Shimazaki J, Sakata M, Tsubota K. Ocular surface changes and discomfort in patients with meibomian gland dysfunction. *Arch Ophthalmol.* 1995;113:1266–1270.
52. Lee SH, Tseng SC. Rose bengal staining and cytologic characteristics associated with lipid tear deficiency. *Am J Ophthalmol.* 1997;124:736–750.
53. Goto E, Shimazaki J, Monden Y, et al. Low-concentration homogenized castor oil eye drops for noninflamed obstructive meibomian gland dysfunction. *Ophthalmology.* 2002;109:2030–2035.
54. Meibomius H. *De Vasis Palpebrarum Novis Epistola Muller.* Helmstadt; 1666.
55. Mackenzie W. *Practical Treatise on the Diseases of the Eye.* 2nd ed. London, United Kingdom: Longman; 1835:149.
56. Elschnig VP. Beitrag zur aetiologie und therapie der chronischen conjunctivitis. *Dtsch Med Wodenschr.* 1908;34:1133–1135.
57. Cowper HW. Meibomian seborrhea. *Am J Ophthalmol.* 1922;5:25–30.
58. Filatov WP. Keratitis meibomiana. *Klin Monatsbl Augenheilkd.* 1930;84:380–384.
59. Gifford SR. Meibomian glands in chronic blepharoconjunctivitis. *Am J Ophthalmol.* 1921;4:489–494.
60. McCulley JP, Dougherty JM, Deneau DG. Classification of chronic blepharitis. *Ophthalmology.* 1982;89:1173–1180.
61. Aubaret. *Bull Soc Franc Ophthal.* 1929;42.
62. Mathers WD, Shields WJ, Sachdev MS, et al. Meibomian gland dysfunction in chronic blepharitis. *Cornea.* 1991;10:277–285.
63. Mathers WD. Ocular evaporation in meibomian gland dysfunction and dry eye. *Ophthalmology.* 1993;100:347–351.
64. Bron AJ, Tiffany JM. The meibomian glands and tear film lipids. Structure, function, and control. *Adv Exp Med Biol.* 1998;438:281–295.
65. Craig JP, Blades K, Patel S. Tear lipid layer structure and stability following expression of the meibomian glands. *Ophthalmic Physiol Opt.* 1995;15:569–574.
66. Norn M. Expressibility of meibomian secretion. Relation to age, lipid precorneal film, scales, foam, hair and pigmentation. *Acta Ophthalmol (Copenh).* 1987;65:137–142.
67. Hom MM, Silverman MW. Displacement technique and meibomian gland expression. *J Am Optom Assoc.* 1987;58:223–226.
68. Romero JM, Biser SA, Perry HD, et al. Conservative treatment of meibomian gland dysfunction. *Eye Contact Lens.* 2004;30:14–19.
69. Korb DR, Greiner, JV. Increase in tear film lipid layer thickness following treatment of meibomian gland dysfunction. *Adv Exp Biol.* 1994;350:293–298.
70. Foulks GN. Blepharitis: lid margin disease and the ocular surface. In: Holland EJ, Mannis MJ, eds. *Ocular Surface Disease: Medical and Surgical Management.* New York, NY: Springer; 2002: chap 3.
71. Mastrota KM. The Meibomian Mastrota paddle [Cynacon/Ocusoft Website]. Available at: [http://www.ocusoft.com/news\\_briefs/art\\_1\\_11\\_06.htm](http://www.ocusoft.com/news_briefs/art_1_11_06.htm). Accessed April 21, 2009.
72. Shimazaki J, Goto E, Ono M, et al. Meibomian gland dysfunction in patients with Sjogren syndrome. *Ophthalmology.* 1998;105:1485–1488.
73. Sotozono C, Ang LP, Koizumi N, et al. New grading system for the evaluation of chronic ocular manifestations in patients with Stevens-Johnson syndrome. *Ophthalmology.* 2007;114:1294–1302.
74. Korb DR, Blackie CA. Meibomian gland diagnostic expressibility: correlation with dry eye symptoms and gland location. *Cornea.* 2008;27:1142–1147.
75. Miller D. Pressure of the lid on the eye. *Arch Ophthalmol.* 1967;78:328–330.
76. Comberg W, Stoewer E. Die Augendruck-steigende Wirkung verschiedener muskelaktionen und ihre Bedeutung. *Z Augenheilk.* 1923;58:617.
77. Norn MS. Semiquantitative interference study of fatty layer of precorneal film. *Acta Ophthalmol (Copenh).* 1979;57:766–774.
78. Doughty MJ, Naase T, Donald C, et al. Visualisation of “Marx’s line” along the marginal eyelid conjunctiva of human subjects with lissamine green dye. *Ophthalmic Physiol Opt.* 2004;24:1–7.
79. Yamaguchi M, Kutsuna M, Uno T, et al. Marx line: fluorescein staining line on the inner lid as indicator of meibomian gland function. *Am J Ophthalmol.* 2006;141:669–675.
80. Norn M. Meibomian orifices and Marx’s line. Studied by triple vital staining. *Acta Ophthalmol (Copenh).* 1985;63:698–700.
81. Henriquez AS, Korb DR. Meibomian glands and contact lens wear. *Br J Ophthalmol.* 1981;65:108–111.
82. Fenga C, Aragona P, Cacciola A, et al. Meibomian gland dysfunction and ocular discomfort in video display terminal workers. *Eye.* 2008;22:91–95.



83. Borchman D, Foulks GN, Yappert MC, et al. Factors affecting evaporation rates of tear film components measured in vitro. *Eye Contact Lens*. 2009;35:32–37.
84. Nichols KK, Nichols JJ, Mitchell GL. The lack of association between signs and symptoms in patients with dry eye disease. *Cornea*. 2004;23:762–770.
85. Linton RG, Curnow DH, Riley WJ. The meibomian glands. An investigation into the secretion and some aspects of the physiology. *Br J Ophthalmol*. 1961;45:718–723.
86. Korb DR, Baron DF, Herman JP, et al. Tear film lipid layer thickness as a function of blinking. *Cornea*. 1994;13:354–359.
87. Goto E, Yagi Y, Matsumoto Y, et al. Impaired functional visual acuity of dry eye patients. *Am J Ophthalmol*. 2002;133:181–186.
88. Goto E, Yagi Y, Kaido M, et al. Improved functional visual acuity after punctal occlusion in dry eye patients. *Am J Ophthalmol*. 2003;135:704–705.
89. Martin NF, Rubinfeld RS, Malley JD, et al. Giant papillary conjunctivitis and meibomian gland dysfunction blepharitis. *CLAO J*. 1992;18:165.
90. Mathers WD, Lane JA, Zimmerman MB. Assessment of the tear film with tandem scanning confocal microscopy. *Cornea*. 1997;16:162–168.
91. Goto E, Tseng SC. Kinetic analysis of tear interference images in aqueous tear deficiency dry eye before and after punctal occlusion. *Invest Ophthalmol Vis Sci*. 2003;44:1897–1905.
92. Korb DR, Greiner JV, Glonek T, et al. Effect of periocular humidity on the tear film lipid layer. *Cornea*. 1996;15:129–134.
93. Bron AJ, Yokoi N, Gafney E, et al. Predicted phenotypes of dry eye: proposed consequences of its natural history. *Ocul Surf*. 2009;7:78–92.
94. Dougherty JM, McCulley JP. Comparative bacteriology of chronic blepharitis. *Br J Ophthalmol*. 1984;68:524–528.
95. Dougherty JM, McCulley JP. Analysis of the free fatty acid component of meibomian secretions in chronic blepharitis. *Invest Ophthalmol Vis Sci*. 1986;27:52–56.
96. McCulley JP, Shine WE. Changing concepts in the diagnosis and management of blepharitis. *Cornea*. 2000;19:650–658.
97. Barton K, Monroy DC, Nava A, et al. Inflammatory cytokines in the tears of patients with ocular rosacea. *Ophthalmology*. 1997;104:1868–1874.
98. Solomon A, Dursun D, Liu Z, et al. Pro- and anti-inflammatory forms of interleukin-1 in the tear fluid and conjunctiva of patients with dry-eye disease. *Invest Ophthalmol Vis Sci*. 2001;42:2283–2292.
99. Afonso AA, Monroy D, Stern ME, et al. Correlation of tear fluorescein clearance and Schirmer test scores with ocular irritation symptoms. *Ophthalmology*. 1999;106:803–810.
100. Macri A, Pflugfelder S. Correlation of the Schirmer I and fluorescein clearance tests with the severity of corneal epithelial and eyelid disease. *Arch Ophthalmol*. 2000;118:1632–1638.
101. Duke-Elder WS, MacFaul PA. The ocular adnexa, part II. Diseases of the eyelids. In: Duke-Elder WS, MacFaul PA, eds. *System of Ophthalmology*. Vol XIII. London, United Kingdom: H. Kimpton; 1974:242.
102. Mori A, Oguchi Y, Goto E, et al. Efficacy and safety of infrared warming of the eyelids. *Cornea*. 1999;18:188–193.
103. Mori A, Shimazaki J, Shimmura S, et al. Disposable eyelid-warming device for the treatment of meibomian gland dysfunction. *Jpn J Ophthalmol*. 2003;47:578–586.
104. Matsumoto Y, Dogru M, Goto E, et al. Efficacy of a new warm moist air device on tear functions of patients with simple meibomian gland dysfunction. *Cornea*. 2006;25:644–650.
105. Fuller JR. Therapeutic eye and eyelid cover. US Patent application publication. US Patent 2004 0237969 A1. December 2, 2004.
106. Mitra M, Menon GJ, Casini A, et al. Tear film lipid layer thickness and ocular comfort after meibomian therapy via latent heat with a novel device in normal subjects. *Eye*. 2005;19:657–660.
107. Di Pascuale MA, Liu TS, Trattler W, et al. Lipid tear deficiency in persistent dry eye after laser in situ keratomileusis and treatment results of new eye-warming device. *J Cataract Refract Surg*. 2005;31:1741–1749.
108. Blackie CA, Solomon JD, Greiner JV, et al. Inner eyelid surface temperature as a function of warm compress methodology. *Optom Vis Sci*. 2008;85:675–683.
109. McCulley JP, Shine WE. The lipid layer of tears: dependent on meibomian gland function. *Exp Eye Res*. 2004;78:361–365.
110. Shine WE, McCulley JP. The role of cholesterol in chronic blepharitis. *Invest Ophthalmol Vis Sci*. 1991;32:2272–2280.
111. Yokoi N, Takehisa Y, Kinoshita S. Correlation of tear lipid layer interference patterns with the diagnosis and severity of dry eye. *Am J Ophthalmol*. 1996;122:818–824.
112. Terada O, Chiba K, Senoo T, et al. Ocular surface temperature of meibomian gland dysfunction patients and the melting point of meibomian gland secretions. *Nippon Ganka Gakkai Zasshi*. 2004;108:690–693.
113. Despa F, Orgill DP, Neuwald J, et al. The relative thermal stability of tissue macromolecules and cellular structure in burn injury. *Burns*. 2005;31:568–577.
114. Olson MC, Korb DR, Greiner JV. Increase in tear film lipid layer thickness following treatment with warm compresses in patients with meibomian gland dysfunction. *Eye Contact Lens*. 2003;29:96–99.
115. Nagymihalyi A, Dikstein S, Tiffany JM. The influence of eyelid temperature on the delivery of meibomian oil. *Exp Eye Res*. 2004;78:367–370.
116. Solomon JD, Case CL, Greiner JV, et al. Warm compress induced visual degradation and Fischer-Schweitzer polygonal reflex. *Optom Vis Sci*. 2007;84:580–587.
117. Lemp MA, Bardfield L, Blackie CA, et al. Evaluation of a novel method of treatment of dry eye. *Invest Ophthalmol Vis Sci*. 2008;127:A154.
118. Paugh JR, Knapp LL, Martinson JR, et al. Meibomian therapy in problematic contact lens wear. *Optom Vis Sci*. 1990;67:803–806.
119. Dougherty JM, McCulley JP. Bacterial lipases and chronic blepharitis. *Invest Ophthalmol Vis Sci*. 1986;27:486–491.
120. Dougherty JM, McCulley JP, Silvano RE, et al. The role of tetracycline in chronic blepharitis. Inhibition of lipase production in staphylococci. *Invest Ophthalmol Vis Sci*. 1991;32:2970–2975.
121. Golub LM, Ramamurthy NS, McNamara TF, et al. Tetracyclines inhibit connective tissue breakdown: new therapeutic implications for an old family of drugs. *Crit Rev Oral Biol Med*. 1991;2:297–321.
122. Li DQ, Lokeshwar BL, Solomon A, et al. Regulation of MMP-9 production by human corneal epithelial cells. *Exp Eye Res*. 2001;73:449–459.
123. Smith VA, Khan-Lim D, Anderson L, et al. Does orally administered doxycycline reach the tear film? *Br J Ophthalmol*. 2008;92:856–859.
124. Souchier M, Joffre C, Gregoire S, et al. Changes in meibomian fatty acids and clinical signs in patients with meibomian gland dysfunction after minocycline treatment. *Br J Ophthalmol*. 2008;92:819–822.
125. Yoo SE, Lee DC, Chang MH. The effect of low-dose doxycycline therapy in chronic meibomian gland dysfunction. *Korean J Ophthalmol*. 2005;19:258–263.
126. Ianaro A, Ialenti A, Maffia P, et al. Anti-inflammatory activity of macrolide antibiotics. *J Pharmacol Exp Ther*. 2000;292:156–163.
127. Luchs J. Efficacy of topical azithromycin ophthalmic solution 1% in the treatment of posterior blepharitis. *Adv Ther*. 2008;25:858–870.
128. Perry HD, Doshi-Carnevale S, Donnenfeld ED, et al. Efficacy of commercially available topical cyclosporine A 0.05% in the treatment of meibomian gland dysfunction. *Cornea*. 2006;25:171–175.
129. Rubin M, Rao SN. Efficacy of topical cyclosporin 0.05% in the treatment of posterior blepharitis. *J Ocul Pharmacol Ther*. 2006;22:47–53.
130. Avunduk AM, Avunduk MC, Varnell ED, et al. The comparison of efficacies of topical corticosteroids and nonsteroidal anti-inflammatory drops on dry eye patients: a clinical and immunocytochemical study. *Am J Ophthalmol*. 2003;136:593–602.
131. Sainz de la Maza Serra SM, Simon Castellvi C, Kabbani O, et al. Nonpreserved topical steroids and punctal occlusion for severe keratoconjunctivitis sicca. *Arch Soc Esp Ophthalmol*. 2000;75:751–756.
132. Hyon JY, Lee YJ, Yun PY. Management of ocular surface inflammation in Sjogren syndrome. *Cornea*. 2007;26:S13–S15.
133. Herman JP, Korb DR, Greiner JV, et al. Treatment of lid wiper epitheliopathy with a metastable lipid emulsion or a corticosteroid. *Invest Ophthalmol Vis Sci*. 2005;46:S 2017.
134. Sullivan BD, Evans JE, Krenzer KL, et al. Impact of antiandrogen treatment on the fatty acid profile of neutral lipids in human meibomian gland secretions. *J Clin Endocrinol Metab*. 2000;85:4866–4873.
135. Krenzer KL, Dana MR, Ullman MD, et al. Effect of androgen deficiency on the human meibomian gland and ocular surface. *J Clin Endocrinol Metab*. 2000;85:4874–4882.
136. Paranjpe DR, Foulks GN. Therapy for meibomian gland disease. *Ophthalmol Clin North Am*. 2003;16:37–42.
137. Gilbard JP, Carter JB, Sang DN, et al. Morphologic effect of hyperosmolarity on rabbit corneal epithelium. *Ophthalmology*. 1984;91:1205–1212.

138. Gilbard JP, Farris RL. Tear osmolarity and ocular surface disease in keratoconjunctivitis sicca. *Arch Ophthalmol*. 1979;97:1642–1646.
139. Korb DR, Greiner JV, Glonek T. The effects of anionic and zwitterionic phospholipids on the tear film lipid layer. *Adv Exp Med Biol*. 2002;506(pt A):495–499.
140. Scaffidi RC, Korb DR. Comparison of the efficacy of two lipid emulsion eyedrops in increasing tear film lipid layer thickness. *Eye Contact Lens*. 2007;33:38–44.
141. Di Pascuale MA, Goto E, Tseng SC. Sequential changes of lipid tear film after the instillation of a single drop of a new emulsion eye drop in dry eye patients. *Ophthalmology*. 2004;111:783–791.
142. Solomon R, Perry HD, Donnenfeld ED, et al. Slitlamp biomicroscopy of the tear film of patients using topical Restasis and Refresh Endura. *J Cataract Refract Surg*. 2005;31:661–663.
143. Novagali Pharma. Cationorm emulsion drop. Available at: <http://www.novagali.com>. Assessed on April 30, 2009.
144. Maskin SL. Intraductal meibomian gland probing relieves symptoms of obstructive MGD. *Invest Ophthalmol Vis Sci*. 2009;4636/D880.
145. Goto E, Dogru M, Fukagawa K, et al. Successful tear lipid layer treatment for refractory dry eye in office workers by low-dose lipid application on the full-length eyelid margin. *Am J Ophthalmol*. 2006;142:264–270.